http://portaildoc.univ-lyon1.fr

Creative commons : Paternité - Pas d'Utilisation Commerciale - Pas de Modification 2.0 France (CC BY-NC-ND 2.0)

http://creativecommons.org/licenses/by-nc-nd/2.0/fr

DEGROLARD
(CC BY-NC-ND 2.0)

UNIVERSITE CLAUDE BERNARD-LYON I
U.F.R. D'ODONTOLOGIE

Année 2020 THESE N° 2020 LYO 1D 054

T H È S E
POUR LE DIPLOME D'ÉTAT DE DOCTEUR EN CHIRURGIE DENTAIRE

Présentée et soutenue publiquement le : 13 octobre 2020

par

DEGROLARD Bertille

Née le 04 septembre 1993, à Dijon (21)

ANALYSE STATISTIQUE DE LA MORPHOLOGIE DU SINUS EN VUE DE LA RÉHABILITATION IMPLANTAIRE DE LA PREMIÈRE MOLAIRE MAXILLAIRE

JURY

Madame le Professeur Kerstin GRITSCH	**Présidente**
Monsieur le Docteur Arnaud LAFON	**Assesseur**
Madame le Docteur Sophie VEYRE	**Assesseur**
Monsieur le Docteur Laurent LAFOREST	**Assesseur**
Monsieur le Docteur Benjamin FITOUCHI	**Assesseur**

DEGROLARD
(CC BY-NC-ND 2.0)

DEGROLARD
(CC BY-NC-ND 2.0)

UNIVERSITE CLAUDE BERNARD-LYON I
U.F.R. D'ODONTOLOGIE

Année 2020 THESE N° 2020 LYO 1D 054

T H È S E
POUR LE DIPLOME D'ÉTAT DE DOCTEUR EN CHIRURGIE DENTAIRE

Présentée et soutenue publiquement le : 13 octobre 2020

par

DEGROLARD Bertille

Née le 04 septembre 1993, à Dijon (21)

ANALYSE STATISTIQUE DE LA MORPHOLOGIE DU SINUS EN VUE DE LA RÉHABILITATION IMPLANTAIRE DE LA PREMIÈRE MOLAIRE MAXILLAIRE

JURY

Madame le Professeur Kerstin GRITSCH	**Présidente**
Monsieur le Docteur Arnaud LAFON	**Assesseur**
Madame le Docteur Sophie VEYRE	**Assesseur**
Monsieur le Docteur Laurent LAFOREST	**Assesseur**
Monsieur le Docteur Benjamin FITOUCHI	**Assesseur**

DEGROLARD
(CC BY-NC-ND 2.0)

UNIVERSITE CLAUDE BERNARD LYON I

Administrateur provisoire	M. le Professeur F. FLEURY
Président du Conseil Académique	M. le Professeur H. BEN HADID
Vice-Président du Conseil d'Administration	M. le Professeur D. REVEL
Vice-Président de la Commission Recherche du Conseil Académique	M. le Professeur J.F MORNEX
Vice-Président de la Commission Formation Vie Universitaire du Conseil Académique	M. le Professeur P. CHEVALIER

SECTEUR SANTE

Faculté de Médecine Lyon Est	Directeur : M. le Professeur G. RODE
Faculté de Médecine et Maïeutique Lyon-Sud Charles Mérieux	Directrice : Mme. la Professeure C. BURILLON
Faculté d'Odontologie	Directrice : Mme. la Professeure D. SEUX
Institut des Sciences Pharmaceutiques et Biologiques	Directrice : Mme. la Professeure C. VINCIGUERRA
Institut des Sciences et Techniques de la Réadaptation	Directeur : M. X. PERROT, Maître de Conférences
Département de Formation et Centre de Recherche en Biologie Humaine	Directrice : Mme. la Professeure A.M. SCHOTT

SECTEUR SCIENCES ET TECHNOLOGIES

UFR des Sciences et Techniques des Activités Physiques et Sportives	Directeur : M. Y. VANPOULLE, Professeur Agrégé
Institut Universitaire de Technologie Lyon 1	Directeur : M. le Professeur C. VITON
POLYTECH LYON	Directeur : M. E. PERRIN
Institut de Science Financière et d'Assurances	Directeur : M. N. LEBOISNE, Maître de Conférences
INSPE	Administrateur provisoire . M. P. CHAREYRON
Observatoire de Lyon	Directrice : Mme la Professeure I. DANIEL
CPE	Directeur : M. G. PIGNAULT
GEP	Administratrice provisoire: Mme R. FERRIGNO
Informatique (Département composante)	Directeur : M. B. SHARIAT
Mécanique (Département composante)	Directeur : M. M. BUFFAT
UFR FS (Chimie, mathématique, physique)	Administrateur provisoire : M. B. ANDRIOLETTI
UFR Biosciences (Biologie, biochimie)	

DEGROLARD
(CC BY-NC-ND 2.0)

FACULTE D'ODONTOLOGIE DE LYON

Doyenne : Mme Dominique SEUX, Professeure des Universités

Vices-Doyens : M. Jean-Christophe MAURIN, Professeur des Universités
Mme Béatrice THIVICHON-PRINCE, Maître de Conférences

Sous-section 56-01 : **Odontologie Pédiatrique et Orthopédie Dento-Faciale**

Professeur des Universités : M. Jean-Jacques MORRIER

Maîtres de Conférences : Mme Sarah GEBEILE-CHAUTY, Mme Claire PERNIER, Mme Béatrice THIVICHON-PRINCE

Maître de Conférences Associée Mme Christine KHOURY

Sous-section 56-02 : **Prévention - Epidémiologie Economie de la Santé - Odontologie Légale**

Professeur des Universités M. Denis BOURGEOIS

Maître de Conférences M. Bruno COMTE

Maître de Conférences Associé M. Laurent LAFOREST

Sous-section 57-01 : **Chirurgie Orale – Parodontologie – Biologie Orale**

Professeur des Universités : M. Jean-Christophe FARGES, Mme Kerstin GRITSCH

Maîtres de Conférences : Mme Anne-Gaëlle CHAUX, M. Thomas FORTIN, M. Arnaud LAFON, M. François VIRARD

Maître de Conférences Associé M. BEKHOUCHE Mourad

Sous-section 58-01 : **Dentisterie Restauratrice, Endodontie, Prothèse, Fonction-Dysfonction, Imagerie, Biomatériaux**

Professeurs des Universités : M. Pierre FARGE, Mme Brigitte GROSGOGEAT, M. Jean-Christophe MAURIN, Mme Catherine MILLET, M. Olivier ROBIN, Mme Dominique SEUX, M. Cyril VILLAT

Maîtres de Conférences : M. Maxime DUCRET, M. Patrick EXBRAYAT, M. Christophe JEANNIN, Mme Marion LUCCHINI, M. Renaud NOHARET, M. Thierry SELLI, Mme Sophie VEYRE, M. Stéphane VIENNOT, M. Gilbert VIGUIE
,

Maître de Conférences Associés M. Hazem ABOUELLEIL

Section 87 : **Sclences Biologiques Fondamentales et Cliniques**
Maître de Conférences Mme. Florence CARROUEL

DEGROLARD
(CC BY-NC-ND 2.0)

À notre jury et présidente,

Madame le professeur Kerstin GRITSCH

Professeure des Universités à l'UFR d'Odontologie de Lyon
Praticien-Hospitalier
Docteur en Chirurgie Dentaire
Docteur de l'Université Lyon I
Responsable de la sous-section Parodontologie
Habilitée à Diriger des Recherches

Je vous remercie de me faire l'honneur de présider ce jury et de juger mon travail.
Merci d'avoir répondu présente et d'avoir accepté ce rôle au dernier moment. Nous n'avons pas eu l'occasion de travailler ensemble lors de mon DES mais les astreintes passées ensemble durant la période de crise sanitaire m'ont permise de faire votre connaissance et de vous apprécier entièrement.
Veuillez trouver dans ce travail l'expression de ma gratitude et mon respect.

DEGROLARD
(CC BY-NC-ND 2.0)

À notre jury de thèse,

Monsieur le Docteur Arnaud LAFON

Maître de Conférences à l'UFR d'Odontologie de Lyon
Praticien-Hospitalier
Docteur en Chirurgie Dentaire
Docteur de l'Université de Bourgogne
Ancien Interne en Odontologie
Ancien Assistant Hospitalo-Universitaire
Spécialiste qualifié en Chirurgie Orale

Je vous remercie pour votre implication, votre accompagnement sincère et sympathique tout au long de ma formation.
Merci pour votre esprit pédagogue et votre volonté de partager vos connaissances théoriques et cliniques durant ces trois années.
Merci de m'avoir fait confiance et de m'avoir formée à l'Implantologie Orale et à la Chirurgie Orale dès le début de mon DES.
Votre dynamisme et votre passion pour la Chirurgie Orale font de vous l'un des meilleurs modèles que j'ai pu suivre lors de mon DES.
Veuillez trouver dans ce travail l'expression de ma profonde gratitude et du respect que j'ai pour vous.

DEGROLARD
(CC BY-NC-ND 2.0)

À notre jury et directrice,

Madame le Docteur Sophie VEYRE

Maître de Conférences à l'UFR d'Odontologie de Lyon
Praticien-Hospitalier
Docteur en Chirurgie Dentaire
Ancien Interne en Odontologie
Docteur de l'Université Lyon I
Spécialiste qualifié en Chirurgie Orale

Je vous remercie pour votre précieuse aide à la rédaction de cette thèse.
Merci pour vos enseignements théoriques et cliniques de la Chirurgie Orale et pour votre implication dans mon évolution durant ces trois années de DES.
Veuillez trouver dans ce travail l'expression de ma gratitude et de mon respect dans le fait que vous êtes une femme chirurgienne-orale et qu'il y en existe encore trop peu.

DEGROLARD
(CC BY-NC-ND 2.0)

À jury et co-directeur,

Monsieur le Docteur Laurent LAFOREST

Maître de Conférences Associée à l'UFR d'Odontologie de Lyon
Docteur en Médecine
Docteur de l'Université Lyon IM

Je vous remercie pour votre implication dans cette étude. Sans vous, nous n'aurions pas eu l'opportunité de mener l'étude jusqu'au bout.
Merci pour votre aide précieuse et votre implication dans la rédaction de ce manuscrit.
Veuillez trouver dans ce travail l'expression de mon respect et de ma gratitude.

DEGROLARD
(CC BY-NC-ND 2.0)

À notre jury,

Monsieur le Docteur Benjamin FITOUCHI

Assistant hospitalo-universitaire au CSERD de Lyon
Ancien Interne en Odontologie
Docteur en Chirurgie Dentaire

Je vous remercie pour votre implication bienveillante et votre aide précieuse tout au long de mes trois années de DES.
Merci pour votre soutien, votre sympathie et votre vision moderne de la Chirurgie Dentaire, vous rendez le métier encore plus passionnant en prouvant qu'il est impossible de s'ennuyer au quotidien lorsqu'on est chirurgien-dentiste grâce à l'évolution perpétuelle des techniques.
Merci de m'avoir fait confiance et de m'avoir permise de me lancer sereinement dans la Chirurgie.
Merci pour tous les excellents moments passés ensemble durant ces trois années et merci d'avance pour les prochains à venir, entre amis.
Veuillez trouver dans ce travail l'expression de mon respect et de ma profonde gratitude que j'ai pour vous.

DEGROLARD
(CC BY-NC-ND 2.0)

DEGROLARD
(CC BY-NC-ND 2.0)

TABLE DES MATIÈRES

1. Introduction **13**

2. Article **15**

2.1. Abstract 15

2.2. Introduction 16

2.3. Materials and Methods 17

2.4. Results 23

2.5. Discussion 29

2.6. Conclusion 32

2.7. Conflicts of interests 32

2.8. Ethics statements 32

3. Conclusion **33**

4. Bibliographie **34**

5. Table des tableaux **37**

6. Table des illustrations **37**

DEGROLARD
(CC BY-NC-ND 2.0)

1. Introduction

Les sinus maxillaires sont au nombre de deux et constituent deux cavités pneumatiques creusant symétriquement les deux os maxillaires de la face dans leur partie postérieure. Ils sont visibles à partir de cinq mois in utero et leur croissance s'établit grâce au processus physiologique de pneumatisation, en suivant la croissance des os maxillaires et des dents maxillaires. (1) (2)
Leur croissance se stabilisent avec l'éruption des troisièmes molaires maxillaires (dents de sagesse) et les sinus atteignent un volume moyen de douze centimètres cubes. (3)
Selon Ata-Ali et coll. (2017) (4) 33,2 à 58% des sinus maxillaires comportent des cloisons , appelées septa d'Underwood (5) pouvant ou non entraîner la création de plusieurs cavités sinusales. Ceux-ci sont principalement localisés dans les zones des premières et des deuxièmes molaires maxillaires (6).

La paroi inférieure du sinus étant étroitement liée à l'os alvéolaire et aux dents maxillaires postérieures, le sinus maxillaire est un élément anatomique essentiel à analyser avant une chirurgie implantaire maxillaire. Au cours de la vie, les volumes des sinus gauches et droits peuvent varier. En effet, après l'avulsion d'une dent maxillaire postérieure, le processus de pneumatisation centrifuge sinusien reprend et s'accompagne d'une résorption centripète de l'os alvéolaire.
Ces deux phénomènes associés représentent deux obstacles importants à l'Implantologie Orale et peuvent compliquer la pose d'un implant standard. (7) (8) (9)

Face à cette situation, deux chirurgies d'augmentation osseuse au niveau du sinus peuvent être réalisées : il peut s'agir de l'élévation du plancher sinusien par une approche crestale indirecte appelée « summers » (10), ou de l'élévation du plancher sinusien par une approche latérale directe appelée « sinus lift » (11). Ces deux techniques chirurgicales visent à réduire partiellement le volume dilaté du sinus maxillaire afin de pouvoir poser un implant de taille standard dans le secteur postérieur maxillaire.

Dans leur étude, Antoun et al. (2003) ont étudié l'édentement maxillaire postérieur nécessitant le soulèvement du sinus maxillaire par voie latérale. Ils ont classifiés les édentements rencontrés en six classes distinctes (I à VI) selon la hauteur et la largeur de la crête alvéolaire et la présence (ou l'absence) d'un décalage vertical et / ou latéral. Ils ont attribué un traitement pré-implantaire différent additionné à un sinus lift (expansion de la crête alvéolaire, régénération osseuse guidée (ROG), greffe d'apposition osseuse, distractions de crête alvéolaire et greffe d'interposition) à chaque classe.

Depuis plusieurs années, il a été démontré que l'imagerie volumétrique par faisceau conique (CBCT) est l'outil de référence en Implantologie Orale (12) (13) (14). D'une part, grâce à la faible dose d'exposition qu'il produit sur les patients, selon les principes généraux de protection contre les rayonnements ionisants et d'autre part grâce à sa capacité à permettre une visualisation précise des éléments constitutifs de la sphère buccale, tels que les éléments relatifs à l'os alvéolaire et au sinus maxillaire selon différents plans de coupe (axial, transversal, frontal), lors d'un bilan pré-implantaire.

L'analyse préalable de la morphologie des sinus maxillaires par imagerie volumétrique à faisceau conique (CBCT) doit permettre aux chirurgiens-dentistes pratiquant l'Implantologie Orale de reconnaître les cas d'édentements pour lesquels une chirurgie d'augmentation osseuse nécessite

DEGROLARD
(CC BY-NC-ND 2.0)

d’être réalisée au niveau de l’édentement de la première molaire maxillaire. Cette analyse englobe les éléments adjacents à l'édentement tels que la présence des secondes prémolaires et des secondes molaires, la proximité de leurs apex avec le plancher sinusien, la longueur et la largeur du sinus maxillaire, en addition à la hauteur et à la hauteur de l’os alvéolaire résiduel au niveau de l’édentement.

Il serait également judicieux de pouvoir augmenter la prédictibilité de connaitre la nécessité d’’avoir recours à une chirurgie d’augmentation osseuse au niveau de la zone édentée de la première molaire maxillaire avant même son avulsion, grâce à l'analyse en amont de toutes les structures constituant le sinus maxillaire évoquées ci-dessus.
À notre connaissance, aucune étude n'a encore été menée sur ce sujet.
Le but de cette étude rétrospective est d'évaluer l'association entre les éléments constitutifs du sinus maxillaire et la hauteur de l’os alvéolaire résiduel au niveau de l’édentement de la première molaire maxillaire afin de mettre en évidence des nouvelles corrélations et de permettre aux chirurgiens-dentistes d'anticiper le recours aux chirurgies d'augmentation osseuse.

DEGROLARD
(CC BY-NC-ND 2.0)

2. Article

« Statistical analysis of sinus morphology with a view to implant rehabilitation in the area of the maxillary first molar.

Bertille Degrolard (DESMBD), Dr. Laurent Laforest (MCU), Dr. Sophie Veyre (MCU).

2.1. Abstract

Purpose: proximity between maxillary sinus and alveolar bone represents a significant obstacle during rehabilitation of the edentulous maxillary first molar by standard implant.
The aim of this study was to evaluate the association between constitutive elements of the maxillary sinus and alveolar bone height (ABH) in the edentulous area of the maxillary first molar (MFM) through patients CBCTs, in order to highlight new correlations and to allow dental surgeons to anticipate the use of bone augmentation surgeries.

Materials and methods: CBCTs of patients with at least the MFM absent were included. Following information was collected then statistically analysed : unilateral or bilateral edentulousness, alveolar bone height (ABH) and alveolar bone width (ABW), sinus length (SL) and sinus width (SW), presence of the maxillary second premolar (MSP) and presence of the maxillary second molar (MSM), their relationship with the maxillary sinus floor (MSF), presence of sinusal septa, presence of general periodontal resorption and presence of vertical and/or lateral gap of the alveolar bone. ABH was classified into 3 groups (class A: ≥8mm; 8mm > class B ≥6mm; class C: <6mm). Statistical analyses consisted of univariate analyses, then bootstrap logistic regressions.

Results: 180 CBCT were included. ABH in the area of the missing MFM under 8 millimeters was significantly more likely retrieved in patients with bilateral edentulousness ($p<0.001$). It was rarely observed when one or both adjacent teeth were present ($p=0.023$), especially when their apices were far from the MSF. ABH significantly decreased when SW increased ($p<0.001$).

Conclusion: this study allowed the discovery of significant correlations between constitutive elements of the maxillary sinus and the alveolar bone height in the area of the edentulous MFM, especially when MSP and MSM are present and far from the MSF, allowing practitioners to anticipate potential surgeries of bone modifications before even the PMM avulsion.

Keywords: Alveolar bone height, maxillary sinus morphology, CBCT, maxillary posterior implant therapy.

DEGROLARD
(CC BY-NC-ND 2.0)

2.2. Introduction

Maxillary sinus is a pneumatic cavity hollowing out the jawbone in its posterior part. It is radiologically visible from five months in utero and its growth follows that of the jawbone and that of the teeth by the physiological process of pneumatisation (1)(2). It stabilises with the maxillary third molars' eruption and reaches an average of twelve cubic centimeters (3).
According to Ata-Ali and al. (2017)(4) 33.2 to 58% of the maxillary sinuses have an Underwood's septa (5) which may or not result in the creation of several sinus cavities. They are mainly located in the maxillary first and second molars' areas (6).

Sinus inferior wall is closely related to the alveolar ridge and posterior maxillary teeth, making the maxillary sinus an essential anatomical feature to be analysed before maxillary implant surgery. During life, volumes of the left and the right sinuses vary. Indeed, after posterior maxillary tooth avulsion, the process of centrifugal pneumatisation of the sinus resumes and centripetal resorption of the alveolar ridge accompanies it.
Both of these phenomena represent significant obstacles to Oral Implantology and can make placement of a standard implant difficult. (7)(8)(9)

Faced with this situation, surgical arrangements for bone augmentation are performed. It can be the elevation of the sinus floor either by an indirect crestal approach, as the summers (10), or by direct lateral approach as the sinus lift (11). These two surgical techniques aim to partially reduce the dilated volume of the maxillary sinus in order to be able to place a standard implant in the posterior sector of the maxilla.

In their study, Antoun and al. (2003) studied posterior maxillary edentulousness requiring sinus grafts and categorised them into six distinct classes (I to VI) according to the height of the alveolar ridge, the width of the alveolar ridge and the presence or absence of a vertical and/or lateral gap. They assigned a different pre-implant treatment in addition to a sinus lift (ridge expansion, guided bone regeneration, bone apposition graft, ridge distractions, and interposition graft) to each class.

For several years, it has been demonstrated that the Cone-Beam Computed Tomography (CBCT) is the reference tool in Oral Implantology (12)(13)(14). On the one hand, thanks to the low dose of exposure that it produces on patients according to the general principles of protection against ionising radiation and on the other hand thanks to its ability to allow precise visualisation of elements of the oral sphere, such as elements relating to the alveolar bone during a pre-implant assessment and in particular the sinus in the posterior maxillary sector, according to different section planes (axial, transverse, frontal).

The prior analysis of sinus morphology through CBCT should allow dental surgeons practicing Implantology to recognise cases of edentulousness for which bone augmentation surgery should be performed on the maxillary first molar. This analysis encompasses elements adjacent to edentulousness such as the presence of the second premolars and the second molars, their proximity to the sinus floor, the length and width of the sinus, in obvious addition to the width and height of the alveolar ridge residual at the level of edentulousness.

It would also be judicious to increase the predictability of having recourse to a bone augmentation in the area of the maxillary first molar even before its avulsion, thanks to the upstream analysis of all the adjacent sinus morphological structures mentioned above.

DEGROLARD
(CC BY-NC-ND 2.0)

To our knowledge, no studies have been conducted on this subject yet.
The aim of this retrospective study was to evaluate the association between the morphology of the sinus and the height of the residual alveolar ridge at the level of the absent maxillary first molar in order to highlight new correlations and to allow dental surgeons to anticipate the use of bone augmentation surgery.

2.3. Materials and Methods

CBCT images collections

The reason for the CBCT scanninng was the pre-implant analysis of patients with at least one first maxillary molar absent, being candidate to have a fixed implant-prosthetic rehabilitation.

High-quality images of CBCT were collected from two Study Centers : the university dental care center and the Edouard Herriot Hospital (both in Lyon) from September 2019 to April 2020.

The retrospective examination of each medical file included all the patients in good health, with at least one first maxillary molar absent.

The exclusion criteria for the CBCT images were as following : patient with implant surgery contraindications, patients with orthodontic treatments or with disturbed normal anatomy of maxillary sinus, oral-sinus communication in area of the maxillary first molar, maxillary premolars or molars with unformed roots or roots resorptions or roots having been treated by apical surgeries.

We retrospectively selected the CBCT images of 138 individuals (73 women and 65 men). The age of these patients was ranged from 24 to 89 years old.

CBCT images analyses :

The CBCT images were all obtained by experiences radiologists trained in the two Study Centers following the « as-low-as-reasonably-achieved » principle. The CBCTs were programmed with the same parameters which are as follows: 90 kV, 12 mA, a voxel size of 150 mm. They reduced the artefacts as much as possible and a adjusted the contrast and brightness of the images.

Cross-sectional views of the maxilla and panoramic cone-beam computed tomography were reconstructed and analysed bye one calibrated clinician from Lyon Dental University Center through a cone-beam computed tomography software package (BlueSky Plan, Libertyville, United States). All variables were measured to the nearest hundredth of a millimetre thanks to the decimal rule tool of the software.

Age and gender have been reported from the patient's medical record.

In addition, the CBCT images were assessed and the following data were recorder in Excel : the side of measurements, the alveolar ridge height and width, the sinus length and width, the presence or absence of maxillary first premolar and/or second molar, their relationship with the maxillary sinus floor, the presence or absence of a sinus septum in the edentulous maxillary first molar area,

DEGROLARD
(CC BY-NC-ND 2.0)

the presence or absence of general periodontal resorption, the presence or absence of vertical and/or lateral shift.

Variables associated with patients' demography :

The sample contains 138 individuals. Among them, 42 presented a bilateral edentulousness resulting in 180 toothlessnesses of one first upper molar. We considered only one CBCT for each single toothlessness; a total of 180 radiographs were collected (mean number of radiograps per patient = 1.30). The different criteria were alveolar bone height (ABH), alveolar bone width (ABW), maxillary sinus length (MSL) and width (MSW), presence of septa, presence of a general periodontal resorption, presence of a vertical and/or a lateral gap. Presence of maxillary first premolar (far, antral or in touch) and that of maxillary second molar (far, antral and in touch) were also collected. Percentages were used for qualitative variables while distributions of quantitative variables were described by mean, SD, median values and quartiles.

Patients were divided into four different age groups : under 50 years-old (YO), between 50.1 and 60 YO, between 60.1 and 70 YO and over 70 YO.
Gender was described in the table either by M for Men or by F for Women.
Edentulousness was classified into 3 groups : unilateral left sector, unilateral right sector and bilateral edentulousness.
Each patient with bilateral edentulousness of the maxillary first molar was analysed in two separate lines (1 and 2). A similar lowercase letter was written on each line to emphasise that it belonged to the same patient, to take into account a potential patient effect.

Variables associated with alveolar ridge :

These variables included alveolar bone height (ABH), alveolar ridge width (ARW), presence of vertical and/or lateral gaps (VG and LG), and Antoun's classification (2003).

ABH, ARW and presence of lateral gap were measured on the cone-beam computed tomography axial-section in the middle of the maxillary first molar toothlessness.

- ABH was the distance measured between the alveolar bone crest and the base of the sinus floor. It was classified in three categories : Class A when ABH is greater or equal to 8 millimeters, class B when the height was between 6 millimeters and strictly inferior to 8 millimeters, and class C when the height was strictly inferior to 6 millimeters.

- ARW was the distance measured in millimeters between the palatal bone crest and the vestibular bone crest.

- VG was measured on the panoramic CBCT reconstruction and was considered present (Yes in the table) is there was a difference between the maxillary sinus floor and the height of the present adjacent teeth.

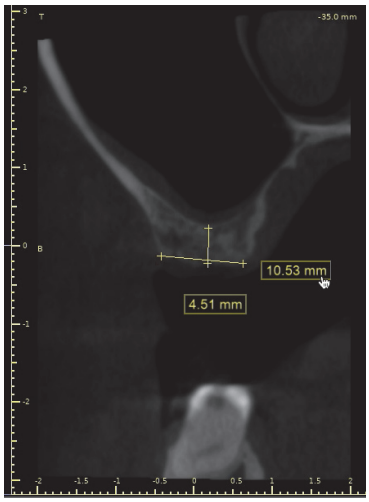

Figure 1: Alveolar bone height and alveolar bone width measurements in millimeters.

DEGROLARD
(CC BY-NC-ND 2.0)

Figure 2: vertical gap (VG) in right sector.

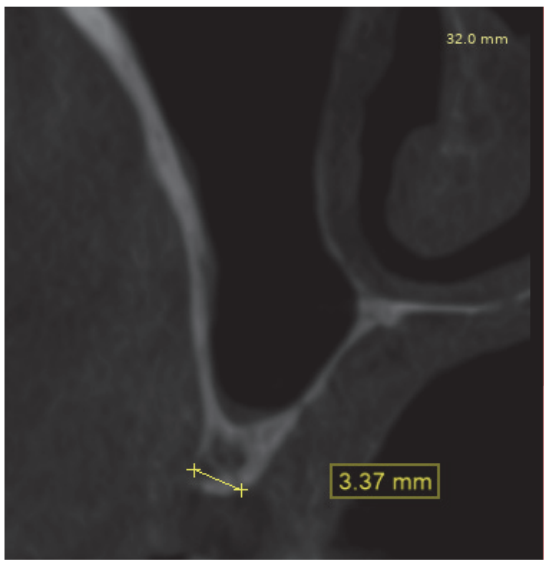

Figure 3: lateral gap (LG) in right sector.

- LG was considered present (Yes in the table) if the alveolar ridge width was strictly inferior to 6 millimeters.

- The Antoun classification was used to subclassify our study's class C (ABHs strictly less than 6 millimeters) : Class I includes 2mm≤ ABH <6mm and ARW ≥6mm; Class II includes ABH<2mm and ARW ≥6mm; Class III includes 2mm≤ ABH <6mm and 3mm≤ ARW <6mm with presence of altered LG; Class IV includes 2mm≤ ABH <6mm and ARW <3mm with presence of altered LG; Class V includes ABH <2mm and ARW <6mm with presence of altered LG; Class VI includes ABH <6mm and ARW variates with presence of altered LG and altered VG.

Variables associated with adjacent teeth :

These variables included presence of the maxillary second premolar (5) and/or molar (7), their apices location related to the maxillary sinus floor (MSF) and the presence of a general periodontal resorption. First and last variables were measured on the panoramic CBCT reconstructed while the apices were observed on the same maxillary axial-section as for the alveolar ridge variables.

- The presence of the second premolar and the second molar were respectively scored 1 and 1 in the table, their absence were scored 0. The presence of an implant in place of one of them was mentioned « implant ».

- The location of the second premolars and second molars' apices related to the MSF was divided into 3 categories: « antral » when root apex extending inside the MSF, « in touch » when root apex contacting with the MSF and « far » when root apex extending outside the MSF. It was the apex of the root closest to the sinus that was taken into account.

- General periodontal resorption was observed when the vestibular and palatal bony cortices are under limites of the dental biological space. Presence was scored 1 and absence was 0.

DEGROLARD
(CC BY-NC-ND 2.0)

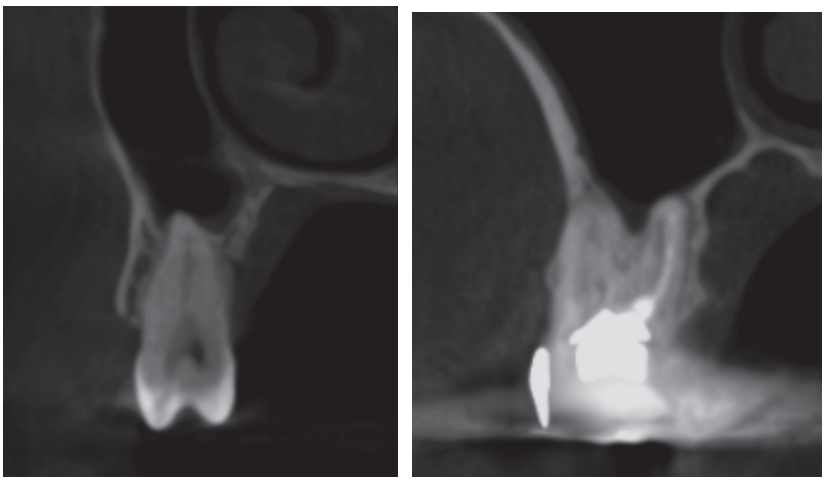

Figure 4: maxillary second premolar (on the left) and molar (on the right) antral through the maxillary sinus.

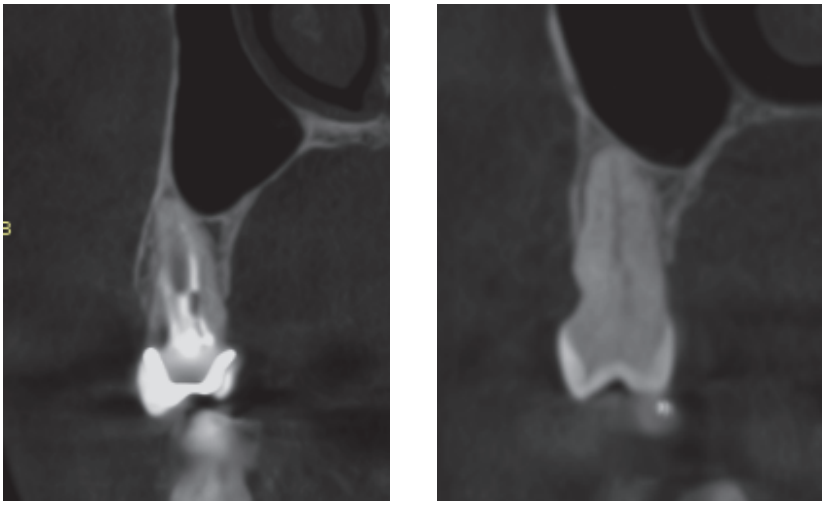

Figure 5: maxillary second premolar (on the left) and molar (on the right) in touch with the maxillary sinus floor.

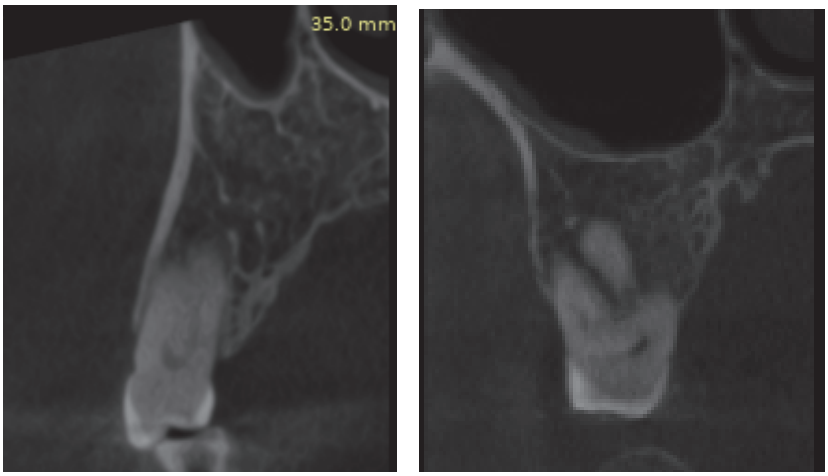

Figure 6: maxillary second premolar (on the left) and molar (on the right) far from the maxillary sinus floor.

DEGROLARD
(CC BY-NC-ND 2.0)

Variables associated with sinus :

These variable consisted of maxillary sinus length (MSL), maxillary sinus width (MSW) and the presence of a septa in the area of the toothlessness maxillary first molar.

- MSL was measured from an imaginary rectilinear line connecting the most internal point of the internal face of the maxillary sinus and the most external point of the external face of the maxillary sinus and facing the top of the lower nasal horn on the panoramic cone-beam CT view. Beforehand, to have the whole sinus, a curvilinear line was created between the most anterior and posterior points of the sinus on the horizontal section of the facial area.

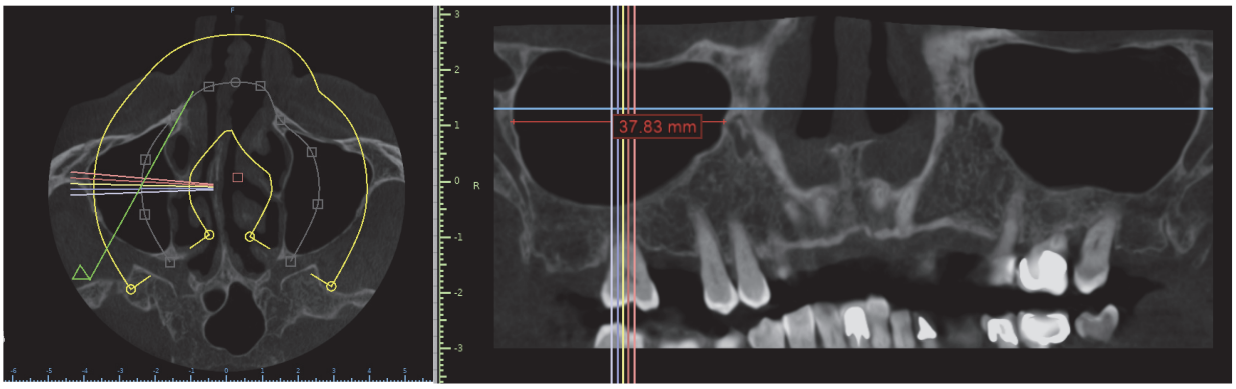

Figure 7: maxillary sinus length measurement on a transversal-section of the CBCT (on the left, and on a panoramic cone beam CT view (on the right).

- MSW was measured from an imaginary rectilinear line connecting the most palatine point of the internal face of the maxillary sinus and the most vestibular point of the external face of the maxillary sinus facing the base of lower nasal horn, on the same maxillary axial-section as for the alveolar ridge variables and location apices adjacent teeth.

- Presence of one septum in the area of the absent maxillary first molar was scored as 1 and absence was scored 0.

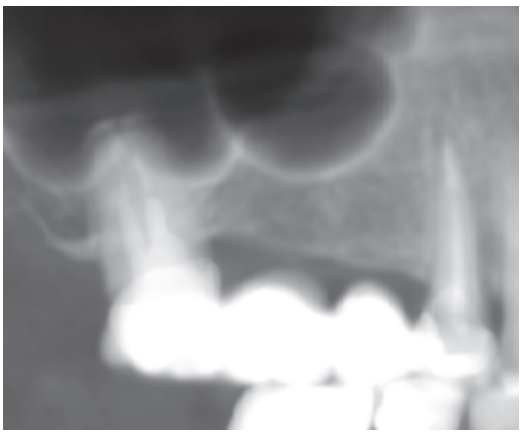

Figure 8: Underwood's septum in the posterior maxillary area, on the panoramic cone beam CT view.

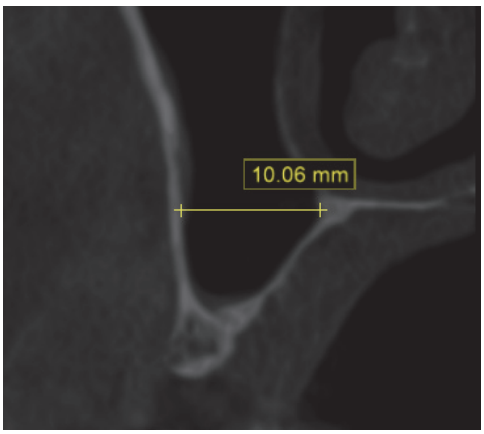

Figure 9: maxillary sinus width measurement on the left sector.

DEGROLARD
(CC BY-NC-ND 2.0)

Variables associated with the ABH, ARW and Antoun's classification :

It includes different implant therapies. In class A, no MSF bone augmentation is required. In class B : one MSF bone augmentation is required : Summers. In class C and according to Antoun Classification (2016) : the MSF bone augmentation required is a sinus lift using the lateral wall technique.
Among class C, in class I, a sinus graft and the simultaneous implant placement can be performed. In cass II, a sinus graft is performed first and the implant placement is done after healing for 6 to 8 months. In class III, a sinus graft and the reduction of the implant's diameter or expansion or guided bone regeneration (GBR) and simultaneous implant placement are performed. In class IV, a sinus graft and an expansion or expansion or GBR or apposition are first performed and implant placement is done after healing for 6 to 8 months. In class V, a sinus graft and an expansion or expansion or GBR or apposition are fist performed and implant placement is done after healing for 6 to 8 months. Eventually in class VI, a sinus graft and a vertical and / or horizontal apposition or a vertical and / or horizontal ROG or vertical bone distraction or interposition graft are performed first and implant placement is done after healing for 6 to 8 months.

Statistical analysis :

Given the limited number of patients with bilateral edentulousness, a mixed model could not be used; a bootstrap approach was used in logistic regressions to take into account correlation between measurements in confidence intervals and p-value calculation.

Dependent variable was the height of residual bone (B or C vs. A category as reference). After univariate, multivariate models were computed. Two models were successively conducted. Model 1 included as the number of present adjacent teeth to the edentulous first molar (maxillary first premolar and/or maxillary second molar) : none, one and both. Model 2 was similar to Model 1, but the number of present adjacent teeth to edentulous first molar was replaced by the respective detailed positions (far, antral, in touch) of both maxillary first premolar and maxillary second molar. Other explanatory variables were included if they presented a significant association between the dependent variables in univariate analyses ($p<0.05$).

DEGROLARD
(CC BY-NC-ND 2.0)

2.4. Results

A total of 138 patients (73 women) were examined at the first implant consultation, corresponding to 180 edentulous maxillary first molars.
Among them, 42 patients presented bilateral edentulousness of the maxillary first molar (Table 1).

Descriptive analyses:

180 preoperative cone-beam CT images were examined. The average alveolar bone height in the area of the missing maxillary first molar was 7.43 millimeters (SD= 1.67). A noticeable proportion of cases presented an alveolar residual bone height strictly lower than 8 millimeters (80,55%). About two thirds (67,22%) belonged to class C, of which the majority are in subclass I (52,63%). (Table 1)

87 and 62 of the 180 CBCTs showed respectively the presence of the maxillary second premolar and the maxillary second molar. Their apices locations were respectively 24,86% far and 12,78% far form the MSF. (Table 1)

Mean sinus width observed on the 180 CBCTs was 14.56 (±-4.17) millimeters and mean sinus length was 38.55 (±3.90) (Table 1).

Inferential analyses:

ABH strictly lower than 8 millimeters was significantly more retrieved in patients with this bilateral edentulousness, both in univariate and multivariate analyses. (Table 2, 3)

The probability of observing an ABH lower than 8 millimeters statistically decreased with the presence of one adjacent tooth or both. Further, ABH was significantly rarely lower than 8 millimeters when maxillary second premolar apices were far from the maxillary sinus floor ($p < 0.001$). Similar significant results were found for MSP apices location, although with a less marked association (Tables 2, 3).

The alveolar bone height in the area of the missing maxillary first molar significantly decreased with the increasing sinus width ($p < 0.001$). (Table 3). Sinus width was not entered in the models due to a collinearity effect with toothlessness variable. No significant association was found with sinus length.

All other variables such as age, gender, presence of vertical and/or lateral gap, presence of one septum and presence of a generalised periodontal resorption did not significantly influence the level of ABH in our present study.

DEGROLARD
(CC BY-NC-ND 2.0)

Table 1: description for patients and dental conditions

Variables	N	%
Patients	138	100 %
Patient's age (n, %)		
<50	28	20.29 %
50.1-60	34	24.64 %
60.01-70	42	30.43 %
>70	34	24.64 %
Gender (n, %)		
Male	65	47.10 %
Female	73	52.90 %
Toothlessness		
Unilateral left	55	39.86%
Unilateral right	41	29.71%
Bilateral	42	30.43%
CBCTs	180	100 %
Alveolar bone width (m, SD)	7.43	1.67
Classification of ABH (n, %)		
A	35	19.44%
B	24	13.33%
C	121	67.22%
Details Class C (1) (n, %)		
I	60	52.63%
II	24	21.05%
III	14	12.28%
IV	0	0 %
V	6	5.26%
VI	10	8.77%
Presence of maxillary first molar toothlessness on the other sector (n, %)	84	46.67%
Presence of maxillary second premolar (2) (n, %)	87	49.15%

DEGROLARD
(CC BY-NC-ND 2.0)

Location of maxillary first premolar apices according to maxillary sinus floor (n, %)		
Far	44	24.86%
Antral	12	6.78%
In touch	31	17.51%
Presence of maxillary second molar (n, %)	62	34.44%
Location of maxillary first premolar apices according to maxillary sinus floor (n, %)		
Far	23	12.78%
Antral	23	12.78%
In touch	16	8.89%
Presence of maxillary first premolar and/or maxillary second molar (n, %)		
None	69	38.98%
One of them	67	37.85%
Both	41	23.16%
Maxillary sinus length in mm (m, SD)	38.55	3.90
Maxillary sinus width in mm (m, SD)	14.56	4.17
Maxillary sinus width detailed into quartiles (n, %)		
First quartile	43	23.89%
Second quartile	45	25.00%
Third quartile	43	23.89%
Last quartile	49	27.22%
Presence of one septum (n, %)	53	29.44%
General periodontal resorption [3] (n, %)	130	75.14%
Vertical gap (n, %)	17	9.44%
Lateral gap (n, %)	28	15.56%

[1]: Computed out of 114 radiographs due to the presence of edentulous patients
[2]: Computed out of 177 radiographs due to the presence of 3 implants
[3]: 7 missing data

DEGROLARD
(CC BY-NC-ND 2.0)

Table 2: Probabilities of observing classes B and C compared to class A through univariate analyses.

Variables	Level	OR	95% CI	p-value
Gender	male/female	0.86	[0.40, 1.95]	0.698
Patient's age	50.01-60/<50YO	1.93	[0.53, 6.67]	0.402
	60.01-70/<50YO	1.33	[0.41, 4.03]	
	<70/<50YO	2.44	[0.76, 10.01]	
Edentulousness of maxillary first molar	Unilateral left/ unilateral right	1.86	[0.77, 4.89]	0.010
	Bilateral/ unilateral right	4.32	[1.61, 17.01]	
Presence of maxillary second premolar	presence/absence	0.50	[0.22, 1.08]	0.072
Location of maxillary second premolar's apices related to maxillary sinus floor	antral/absence	1.86	[0.33, 3.65]	<0.001
	in touch/absence	5.06	[0.98, 8.26]	
	far/ absence	0.20	[0.09, 0.46]	
Presence of maxillary second molar	presence/ absence	0.41	[0.19, 0.83]	0.020
Location of maxillary second molar's apices related to maxillary sinus floor	antral/ absence	3.70	[0.78, 6.31]	<0.001
	in touch/ absence	0.61	[0.20, 2.53]	
	far/ absence	0.06	[0.01, 0.16]	
Number of maxillary adjacent teeth form the edentulous maxillary first molar area	1/none	0.26	[0.07, 0.69]	0.014
	2/none	0.26	[0.07, 0.71]	
Maxillary sinus width	second quartile/ first quartile	2.29	[0.91, 6.66]	<0.001
	third quartile/ first quartile	4.03	[1.67, 13.73]	
	last quartile/ first quartile	15.37	[4.17, 48.13]	

DEGROLARD
(CC BY-NC-ND 2.0)

Maxillary sinus length	second quartile/ first quartile	1.03	[0.36, 3.20]	0.988
	third quartile/ first quartile	1.09	[0.37, 3.87]	
	last quartile/ first quartile	1.16	[0.38, 4.43]	
Presence of a septum	presence/ absence	1.86	[0.78, 5.54]	0.163
Generalised periodontal resorption	presence/ absence	1.27	[0.44, 3.20]	0.554
Lateral gap	presence/ absence	0.86	[0.38, 3.01]	0.778

DEGROLARD
(CC BY-NC-ND 2.0)

Table 3: Probabilities of observing classes B and C compared to class A through multivariate analyses.

Variable	Level	OR	95% CI	p-value
Edentulousness	unilateral left/ unilateral right	1.65	[0.60, 4.53]	<0.001
	bilateral/ unilateral right	4.00	[1.37, 15.75]	
Number of maxillary adjacent teeth form the edentulous maxillary first molar	1/none	0.28	[0.07, 0.74]	0.023
	2/none	0.30	[0.08, 0.87]	

Table 4: Probabilities of observing classes B and C compared to class A through multivariate analyses.

Variable	Level	OR	95% CI	p-value
Edentulousness	unilateral left/ unilateral right	3.44	[0.96, 12.74]	0.003
	bilateral/ unilateral right	7.88	[2.01, 43.35]	
Location of maxillary second premolar's apices from the MSF	antral/absence	1.68	[0.18, 5.85]	<0.001
	in touch/ absence	8.18	[0.87, 28.35]	
	far/absence	0.24	[0.06, 0.75]	
Location of maxillary second premolar's apices from the MSF	antral/absence	4.32	[0.44, 12.17]	<0.001
	in touch/ absence	0.53	[0.16, 2.64]	
	far/absence	0.07	[0.01, 0.24]	

DEGROLARD
(CC BY-NC-ND 2.0)

2.5. Discussion

The results of this study suggest that the majority of cases with edentulousness of the maxillary first molar require bone management prior to implant placement and they also suggest that there are correlations between maxillary sinus morphology and the residual alveolar ridge height. CBCTs of patients with unilateral or bilateral edentulousness of at least the maxillary first molar were included in the study and used to assess various parameters. Measurements were made on different axial slices of the CBCT: the height and the width of the alveolar ridge, the width of the maxillary sinus, the presence of adjacent teeth and their proximity to the sinus floor and the presence of a lateral gap of the alveolar ridge. Sinus length, the presence of unilateral or bilateral edentulousness of the maxillary first molar, presence of a vertical gap and presence of generalised periodontal resorption were assessed on panoramic sections reconstructed from CBCTs. Age and gender were taken from medical records. Data was analysed using Bluesky Plan software and filed in Excel computer spreadsheet.
Out of 138 study subjects, 180 CBCTs were analysed, 67.22% had an alveolar ridge height of less than 6 millimeters (class C), 37.85% had at least one adjacent tooth present and respectively 24.9 % and 9% of second premolars and second molars were distant from the sinus floor; 42 subjects presented with bilateral edentulousness.

Some studies conclude that centrifugal sinus pneumatisation is greater during avulsion of the maxillary second molars and premolars (15) while others observe greater pneumatisation during avulsion of the maxillary first molar. (16).
Gu and al. (2018)(17) concluded in their study that "forward" pneumatisation of the maxillary sinus was observed after the maxillary first molar's avulsion. In the present study, our results bear witness to this and significantly prove that the larger the sinus, the lower the height of the alveolar ridge at the level of the maxillary molar ($p < 0.05$). These are consistent with the results of the study of Chan and al. (2014)(18) who concluded that the width of the sinus was greater at the level of the molar sites and that the alveolar ridge at the level of the latter had a lower height.
Following avulsions of the posterior maxillary sectors and in parallel with sinus pneumatisation, a phenomenon of centripetal resorption of the alveolar ridge is observed. It may be the cause of a lateral gap. The latter was mentioned by Antoun and al. (2016)(19) as an alveolar ridge width less than 6 millimeters. Although we found it at 67.86% in the class C cases of our study (bone height less than 6 millimeters), we did not find a significant correlation between it and the height of the residual alveolar bone. in our study.

Maxillary first molars erupt into the oral cavity at age six. These are usually the first permanent teeth to be infected, processed and then avulsed.
Implant treatment is not possible before the end of growth and the alveolar bone continues to be resorbed gradually although edentulousness is rehabilitated by another prosthetic solution (joint or removable prosthesis). Wagner and al. (2017)(20) concluded that extensive centripetal resorption of the bone ridge and concomitant slight pneumatisation of the sinus walls was accentuated by long-lasting edentulousness in the maxillary molar region.
In the present study, this may explain that the majority of sites with the missing maxillary first molar have a residual alveolar ridge height of less than 8 millimeters and require bone management prior to implant placement. These results are similar to those of Padhye and al. (2020)(21), explaining that 67.83% of the molar sites analysed in the 250 CBCTs included in their study had a ridge height of less than 8 millimeters.

DEGROLARD
(CC BY-NC-ND 2.0)

After examining fixed anatomical landmarks on panoramic x-rays of patients before and after dental avulsion, Sharan and al. (2008)(15) concluded that centripetal resorption of the alveolar ridge and centrifugal sinus pneumatisation were increased in cases of avulsion of two or more adjacent maxillary posterior teeth.
Conversely, when the second premolars and the second molars are present mesial and distal to the edentulousness of the maxillary first molar, the results of our study indicate a significant maintenance of the height of the edentulous alveolar ridge greater than 8 millimeters. These adjacent teeth would play a role of "tent stake": according to Wolff's laws (22), the remodelling of the alveolar ridge after avulsion of a single tooth could be conditioned by the presence of adjacent teeth; permanent masticatory function of the latter would maintain the sinus floor nearly its original position, counteract the phenomenon of centrifugal sinus pneumatisation and slow down centripetal alveolar resorption.
Hansson and al. (2012)(23) concluded in their study: "the reduction in the vestibular to palatal dimension as well as the sinusal to alveolar dimension of the alveolar ridge, commonly observed after dental avulsion, can be explained by the physiological law according to which maintenance of bone anatomy requires some daily stress or strain stimulus. "
They also admitted that more aggressive ridge resorption was observed when several adjacent teeth were avulsed in a posterior maxillary area due to their lack of masticatory function.

Phenomenon of maintaining alveolar bone height at the area of the missing maxillary first molar is all the more important when the positions of the apices of adjacent teeth are far from maxillary sinus ($p < 0.05$). One could imagine that the maxillary first molar was in the same configuration far from the sinus floor before its avulsion, leading to a bone height greater than 6 millimeters even after post-extraction resorption compared to a maxillary first molar antral or in contact. with the sinus floor.

Wolff's laws (22) could also explain the significantly increased probability of having a residual bone height less than 6 millimeters when there is the presence of bilateral edentulousness of the maxillary first molars compared to unilateral edentulousness in our present study. Indeed, when a patient has only one posterior maxillary sector in the mouth, the remaining maxillary teeth undergo significant masticatory stresses weakening their periodontium and generating premature bone resorption; If we add neglected oral hygiene and infectious complications on overused teeth, we observe a significant reduction in the quality and quantity of bone before and after their avulsion, preventing the installation of a standard implant after oral cleaning, without prior bone adjustments.
The fact that we included in our study completely edentulous patients with symmetrically advanced posterior maxillary resorption is a second explanation for this significant correlation between the bilaterality of edentulousness of the maxillary first molar and low residual alveolar ridge height in this study. area (less than 6 millimeters). Further studies focusing only on this parameter should be established in the future in order to provide further explanation.

Underwood septa are bony structures present in both toothed and toothless areas (24). Although statistically more present in atrophied edentulous areas according to Pommer and al. (2012)(25), the results of our study show no significant correlation between presence of septa and height of the residual alveolar ridge. Dursun and al. (2019)(26) were of the opinion that septa allowed maintenance of alveolar ridge height rather than promoting sinus expansion as argued by Keceli and al. (2017)(27).

DEGROLARD
(CC BY-NC-ND 2.0)

Although the probability of having low subsinus bone height in the presence of periodontal resorption was increased in our study (OR = 1.27), we did not find a significant correlation between these two parameters. Acharya A. and al (2019)(28) concluded that periodontal resorption was significantly related to a small height of residual sub-sinus bone according to ethnicity (found in the Indian, Asian and Chinese populations of Hong Kong) and that it was predominantly present in cases where the height of alveolar ridge was less than 8 millimeters and its width was less than 6 millimeters.

Limitations of the study:

We were unable to statistically examine the correlation between vertical gap and residual alveolar bone height because we lacked comparison data (CBCT of completely edentulous patients). Pramstraller and al. (2011)(29) concluded after computed tomography analysis of 127 patients, that absence of two teeth adjacent to the edentulous site negatively affected the relative vertical position of alveolar ridge, leading to the appearance of a vertical gap.
In 2016, Antoun and al.(2016)(19) focused on presence of a vertical gap only essentially in cases where a lateral gap was already present. However, we were confronted in our study, with CBCTs showing presence of a vertical gap of edentulous bone crest at the level of the maxillary first molars in the cases belonging to class A, that is to say where alveolar bone height was greater than 8 millimeters.

A second limitation of this study is that it is retrospective and we have no knowledge of the time elapsed between the avulsion of the maxillary first molar and pre-implant CBCT. For greater precision, future studies should be prospective and data should be collected before the avulsion of the maxillary first molar and after healing of the socket.

Openness to future studies:

Although we have brought to light certain significant correlations between sinus morphology and alveolar bone height, some studies show that it is possible to slow down the phenomena of centrifugal sinus pneumatisation and centripetal alveolar resorption by placing Alveolar Ridge Preservation techniques (30).

DEGROLARD
(CC BY-NC-ND 2.0)

2.6. Conclusion

Within the limitations of this statistical study, it can be concluded that edentulousness in the site of the maxillary first molar requires in most cases bone augmentation surgery in the maxillary sinus before the placement of a standard implant, whether by alveolar vertical approach thanks to the summers or by lateral approach thanks to the sinus lift.

Bilateral edentulousness of the maxillary first molar as well as the presence of a large sinus are two elements statistically associated with a residual alveolar ridge height of less than 8 millimeters at the level of the maxillary first molar.

The presence of the adjacent teeth in the area of the edentulous maxillary first molar (maxillary second premolars and maxillary second molars) as well as their apices location away from the sinus floor reduce the risk to have an alveolar bone height lower than 8 millimeters, favouring the placement of a standard implant in this area without any bone augmentation surgeries.

2.7. Conflicts of interests

We have no conflicts of interests.

2.8. Ethics statements

No ethics approval or patients' consent was required for this paper.

DEGROLARD
(CC BY-NC-ND 2.0)

3. Conclusion

Dans les limites de cette étude statistique rétrospective, nous pouvons confirmer l'hypothèse de départ qui supposait que la majorité des cas présentant un édentement de la première molaire maxillaire nécessitaient une chirurgie d'augmentation osseuse avant la pose d'un implant standard. En effet, l'édentement bilatéral des deux premières molaires maxillaires chez un même patient ainsi qu'un large sinus sont deux éléments statistiquement associés à une hauteur d'os alvéolaire inférieure à 8 millimètres, ne permettant pas la pose d'un implant standard directement.
À l'inverse, cette étude permet de démontrer que la présence d'une ou des deux dents adjacentes à l'édentement de la première molaire maxillaire (la deuxième prémolaire et la deuxième molaire maxillaire) ainsi que la localisation de leurs apex à distance du plancher sinusien réduisent les risques d'avoir une faible hauteur d'os alvéolaire permettant la pose d'un implant standard sans aménagement osseux préalable.

DEGROLARD
(CC BY-NC-ND 2.0)

4. Bibliographie

(1) Del Fabro M, Testori T. Maxillary sinus surgery and alternatives in treatment: Anatomy of the maxillary sinus. Berlin: Quintessence; 2009. [Links]

(2) Sánchez-Pérez A, Boracchia AC, López-Jornet P, Boix-García P. Characterization of the Maxillary Sinus Using Cone Beam Computed Tomography. A Retrospective Radiographic Study. Implant Dent. 2016 Dec;25(6):762-9.

(3) GAUDY J.F. Anatomie clinique. Editeur Editions CdP Collection JPIO, 2007).

(4) Ata-Ali J, Diago-Vilalta JV, Melo M, et al. What is the frequency of anatomical variations and pathological findings in maxillary sinuses among patients subjected to maxillofacial cone beam computed tomography? A systematic review. Med Oral Patol Oral Cir Bucal. 2017;22(4):e400-e409. Published 2017 Jul 1.

(5) Maestre-Ferrín L, et al. Maxillary sinus septa: a systematic review. Med Oral Patol Oral Cir Bucal 2010;15(2):e383–6.

(6) Bornstein MM, Seiffert C, Maestre-Ferrín L, Fodich I, Jacobs R, Buser D, et al. An Analysis of Frequency, Morphology, and Locations of Maxillary Sinus Septa Using Cone Beam Computed Tomography. Int J Oral Maxillofac Implants. 2016;31:280-7.

(7) Dod A, Kumar A, Panda A, Pandita A, Vikhankar B. indirect Sinus lift: a simplified approach for implant placement in posterior maxilla. JOADMS 2016; june; 2(2):112-115.

(8) Antoun H, El-Zoghbi H, Cherfane P, Missika P. Les ostéotomes de Summers: Une alternative au volet latéral pour les soulevés de sinus ? Implantodontie 2003; 12(4): 3-9.

(9) Chanavaz M. Maxillary sinus: anatomy, physiology, surgery, and bone grafting related to implantology--eleven years of surgical experience (1979-1990). J Oral Implantol. 1990;16(3):199-209.

(10) SUMMERS A new concept in maxillary implant sugery : the osteotome technique Compendium. 1994 Feb : 15(2), 154-6, 158

(11) PL. BOYNE, RA. JAMES Sinus lift: Grafting of the maxillary sinus floor with autogenous marrow bone. Journ. of Oral. Surgery 1980 ; 38 : 613-616 1.R.

(12) Mafee MF, Tran BH, Chapa AR. Imaging of rhinosinusitis and its complications: Plain film, CT, and MRI. Clin Rev Allergy Immunol 2006;30:165-186

(13) Howe RB. First molar radicular bone near the maxillary sinus: a comparison of CBCT analysis and gross anatomic dissection for small bony measurement. Oral Surg Oral Med Oral Pathol Oral Radiol Endod. 2009;108(2):264-269.

(14) Jacobs R, Salmon B, Codari M, Hassan B, Bornstein MM. Cone beam computed tomography in implant dentistry: recommendations for clinical use. BMC Oral Health. 2018;18(1):88. Published 2018 May 15.

(15) Sharan A, Madjar D. Maxillary sinus pneumatization following extractions: a radiographic study. Int J Oral Maxillofac Implants. 2008;23(1):48-56.

DEGROLARD
(CC BY-NC-ND 2.0)

(16) Alqahtani S, Alsheraimi A, Alshareef A, et al. Maxillary Sinus Pneumatization Following Extractions in Riyadh, Saudi Arabia: A Cross-sectional Study. Cureus. 2020;12(1):e6611. Published 2020 Jan 9.

(17) Gu Y, Sun C, Wu D, Zhu Q, Leng D, Zhou Y. Evaluation of the relationship between maxillary posterior teeth and the maxillary sinus floor using cone-beam computed tomography. BMC Oral Health. 2018;18(1):164. Published 2018 Oct 3.

(18) Chan HL, Suarez F, Monje A, Benavides E, Wang HL. Evaluation of maxillary sinus width on cone-beam computed tomography for sinus augmentation and new sinus classification based on sinus width. Clin Oral Implants Res. 2014;25(6):647-652.

(19) Antoun H. Le défi des greffes de sinus par voie latérale. Journal of Odonto Stomatology. 2016.

(20) Wagner F, Dvorak G, Nemec S, Pietschmann P, Figl M, Seemann R. A principal components analysis: how pneumatization and edentulism contribute to maxillary atrophy. Oral Dis. 2017;23(1):55-61.

(21) Padhye NM, Bhatavadekar NB. Quantitative Assessment of the Edentulous Posterior Maxilla for Implant Therapy: A Retrospective Cone Beam Computed Tomographic Study. J Maxillofac Oral Surg. 2020;19(1):125-130.

(22) Wolff J. Das Gesetz der Transformation der Knochen . Berlin: August Hirschwald, 1892 [Google Scholar]

(23) Stig Hansson 1 et Anders Halldin 1, 2. Résorption de la crête alvéolaire après extraction dentaire: une conséquence d'un principe fondamental de la physiologie osseuse. J Dent Biomech . 2012.

(24) Schriber M, von Arx T, Sendi P, Jacobs R, Suter VG, Bornstein MM. Evaluating Maxillary Sinus Septa Using Cone Beam Computed Tomography: Is There a Difference in Frequency and Type Between the Dentate and Edentulous Posterior Maxilla?. Int J Oral Maxillofac Implants. 2017;32(6):1324-1332.

(25) Pommer B, Ulm C, Lorenzoni M, Palmer R, Watzek G, Zechner W. Prevalence, location and morphology of maxillary sinus septa: systematic review and meta-analysis. J Clin Periodontol. 2012;39(8):769-773.

(26) Dursun E., Keceli H., Dolgun A.;Velasco-Torres M., Olculer M. Maxillary Sinus and Surrounding Bone Anatomy With Cone Beam Computed Tomography After Multiple Teeth Loss, Implant Dentistry: June 2019 - Volume 28 - Issue 3 - p 226-236

(27) Keceli, Huseyin Gencay DDS, PhD*; Dursun, Erhan DDS, PhD*; Dolgun, Anil PhD†; Velasco-Torres, Miguel DDS, PhD‡; Karaoglulari, Suzan DDS§; Ghoreishi, Reihaneh DMD¶; Sinjab, Khaled DDS‖; Sheridan, Rachel A. DDS, MS#; Kubilius, Marius DDS, PhD**; Tözüm, Melek D. DDS, PhD††; Galindo-Moreno, Pablo DDS, PhD‡‡; Yilmaz, Hasan Guney DDS, PhD§§; Wang, Hom-Lay DDS, MS, PhD¶¶; Juodzbalys, Gintaras DDS, PhD‖‖; Tözüm, Tolga F. DDS, PhD## Evaluation of Single Tooth Loss to Maxillary Sinus and Surrounding Bone Anatomy With Cone-Beam Computed Tomography, Implant Dentistry: October 2017 - Volume 26 - Issue 5 - p 690-699

(28) Acharya A, Hao J, Mattheos N, Chau A, Shirke P, Lang NP. Residual ridge dimensions at edentulous maxillary first molar sites and periodontal bone loss among two ethnic cohorts seeking tooth replacement. Clin Oral Implants Res. 2014;25(12):1386-1394.

DEGROLARD
(CC BY-NC-ND 2.0)

(29) Pramstraller M, Farina R, Franceschetti G, Pramstraller C, Trombelli L. Ridge dimensions of the edentulous posterior maxilla: a retrospective analysis of a cohort of 127 patients using computerized tomography data [published correction appears in Clin Oral Implants Res. 2011 Feb;22(2):235]. Clin Oral Implants Res. 2011;22(1):54-61.

(30) Lombardi T, Bernardello F, Berton F, et al. Efficacy of Alveolar Ridge Preservation after Maxillary Molar Extraction in Reducing Crestal Bone Resorption and Sinus Pneumatization: A Multicenter Prospective Case-Control Study. Biomed Res Int. 2018;2018:9352130. Published 2018 Nov 4.

DEGROLARD
(CC BY-NC-ND 2.0)

5. Table des tableaux

Table 1	Description of patients and dental conditions	24
Table 2	Probabilities of observing classes B and C compared to class A through univariate analyses.	26
Table 3	Probabilities of observing classes B and C compared to class A through multivariate analyses.	28
Table 4	Probabilities of observing classes B and C compared to class A through multivariate analyses.	28

6. Table des illustrations

Figure 1	Alveolar bone height and alveolar bone width measurements in millimeters.	18
Figure 2	Vertical gap (VG) in right sector.	19
Figure 3	Lateral gap (LG) in right sector.	19
Figure 4	Maxillary second premolar (on the left) and molar (on the right) antral through the maxillary sinus.	20
Figure 5	Maxillary second premolar (on the left) and molar (on the right) in touch with the maxillary sinus floor.	20
Figure 6	Maxillary second premolar (on the left) and molar (on the right) far from the maxillary sinus floor.	20
Figure 7	Maxillary sinus length measurement on a transversal-section of the CBCT (on the left, and on a panoramic cone beam CT view (on the right).	21
Figure 8	Underwood's septum in the posterior maxillary area, on the panoramic cone beam CT view.	21
Figure 9	Maxillary sinus width measurement on the left sector.	21

DEGROLARD
(CC BY-NC-ND 2.0)

DEGROLARD
(CC BY-NC-ND 2.0)

	N° 2020 LYON 1D 054

DEGROLARD (Bertille) - Analyse statistique de la morphologie du sinus en vue de la réhabilitation implantaire de la première molaire maxillaire.
(Thèse : Chir. Dent. : Lyon : 2020.054)
N°2015 LYON 1D 054

Objectif: la proximité entre le sinus maxillaire et l'os alvéolaire représente un obstacle important lors de la réhabilitation implantaire standard de la première molaire maxillaire. Le but de cette étude est d'évaluer l'association entre les éléments constitutifs du sinus maxillaire et la hauteur de l'os alvéolaire dans la zone édentée de la première molaire maxillaire sur les imageries volumétriques par faisceau conique des patients.

Matériels et méthodes: les CBCT des patients avec au moins la première molaire maxillaire absente ont été inclus. 14 variables ont été collectées puis analysées statistiquement.

Résultats: la hauteur d'os alvéolaire inférieure à 8 millimètres dans l'édentement de la première molaire maxillaire était significativement plus susceptible d'être retrouvée chez les patients présentant un édentement bilatéral de la première molaire maxillaire ($p < 0,001$). Ce phénomène était rarement observé lorsqu'une ou les deux dents adjacentes étaient présentes ($p = 0,023$), en particulier lorsque leurs apex se localisaient à distance du plancher sinusien. la hauteur d'os alvéolaire diminuait significativement lorsque la largeur augmentait ($p < 0,001$).

Conclusion: cette étude permet de mettre en évidence des corrélations significatives entre les éléments constitutifs du sinus maxillaire et la hauteur de l'os alvéolaire dans la zone édentée de la première molaire maxillaire, permettant aux praticiens d'anticiper les potentiels aménagements osseux à réaliser lors de la réhabilitation implantaire de la première molaire maxillaire.

Rubrique de classement :		Implantologie
Mots clés :		- Hauteur de l'os alvéolaire - Morphologie du sinus maxillaire - Imagerie volumétrique par faisceau conique - Thérapie implantaire postérieure maxillaire
Mots clés en anglais :		- Alveolar bone height - Maxillary sinus morphology - CBCT - Maxillary posterior implant therapy
Jury :	**Présidente :** **Assesseurs :**	Madame le Professeur Kerstin Gritsch Monsieur le Docteur Arnaud Lafon Madame le Docteur Sophie Veyre Monsieur le Docteur Laurent Laforest Monsieur le Docteur Benjamin Fitouchi
Adresse de l'auteur :		Bertille Degrolard 7 rue des Quatre Chapeaux 69002 LYON

DEGROLARD
(CC BY-NC-ND 2.0)